

**Il Mio Paziente Non Ci Vede.
Forse Ho Capito Perché...
Ma Non Mi Fido !**

Fabrizio I. Camesasca, MD ¹

Vincenzo Isola, MD ²

Paolo Vinciguerra, MD^{1, 3}

Alfredo Pece, MD ²

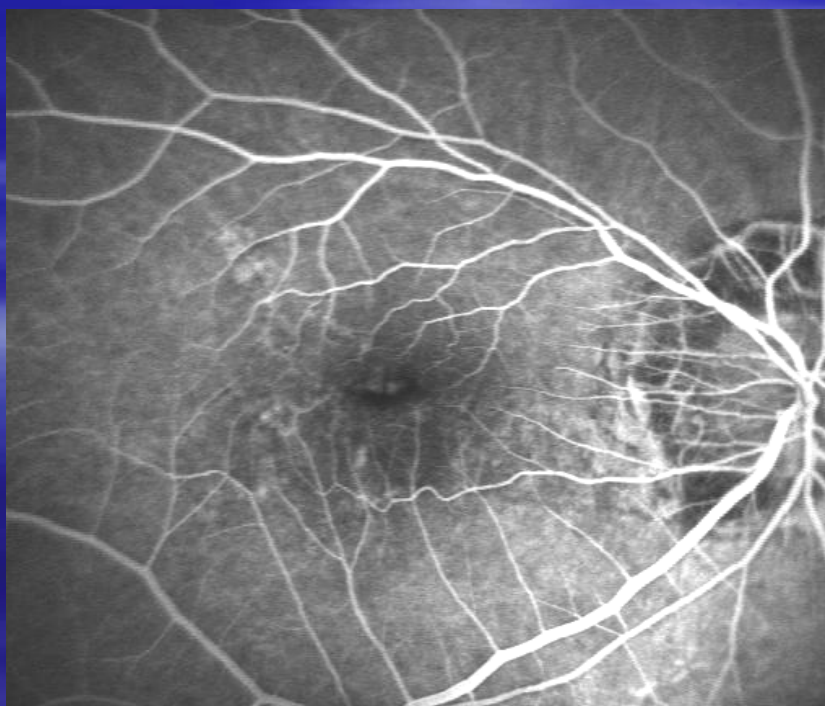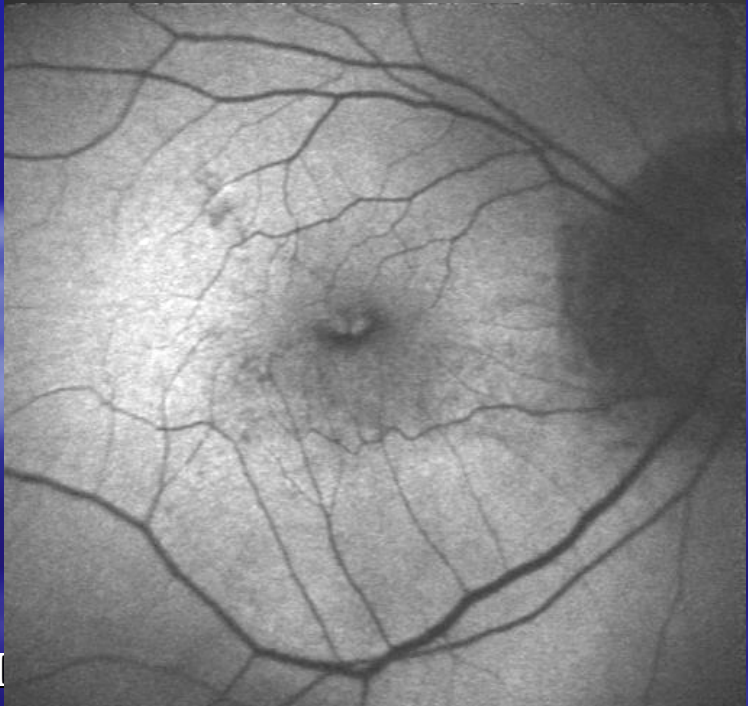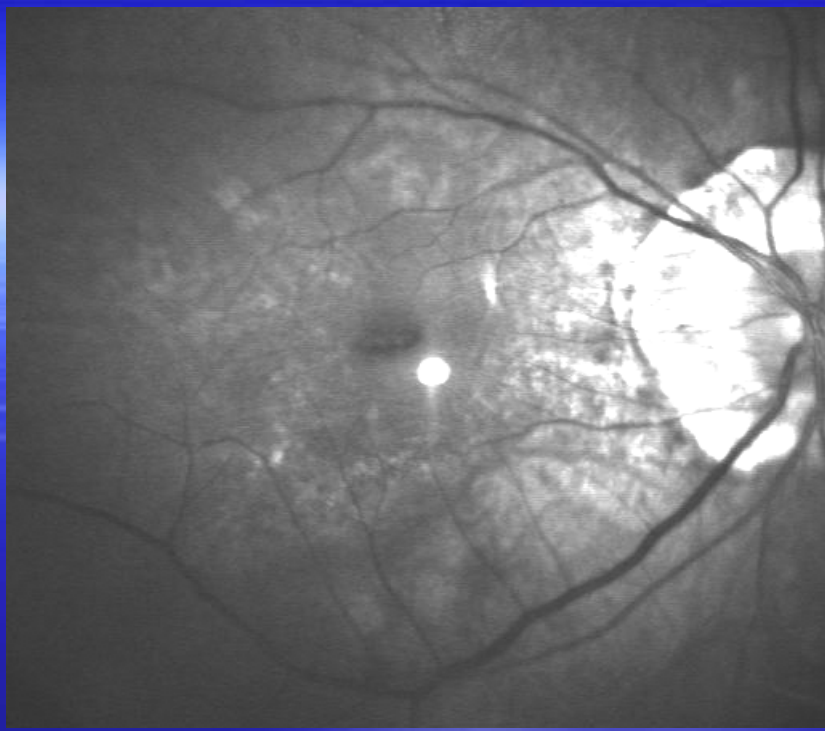
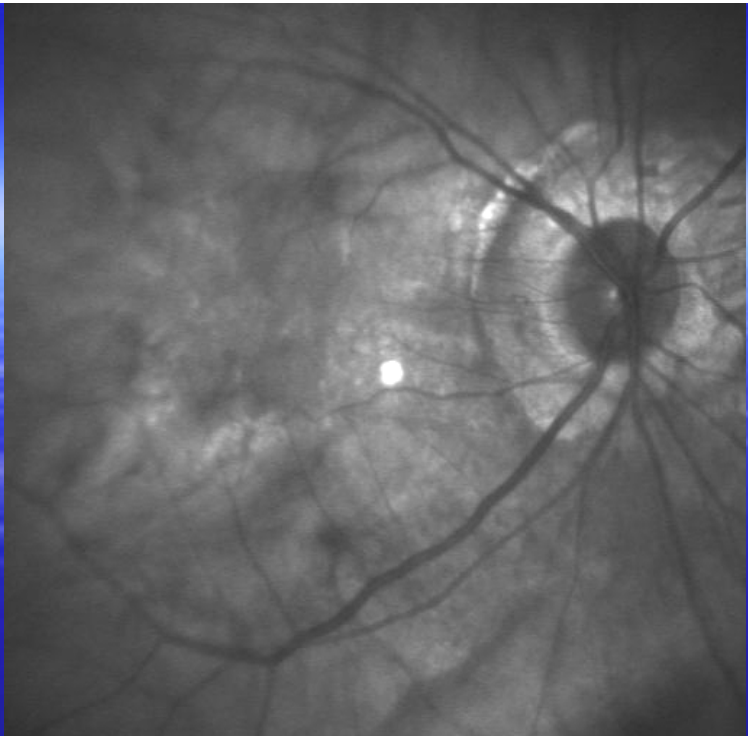
¹Dept of Ophthalmology, Istituto Clinico Humanitas

²Dept of Ophthalmology, Melegnano H

³Columbus, Ohio State University

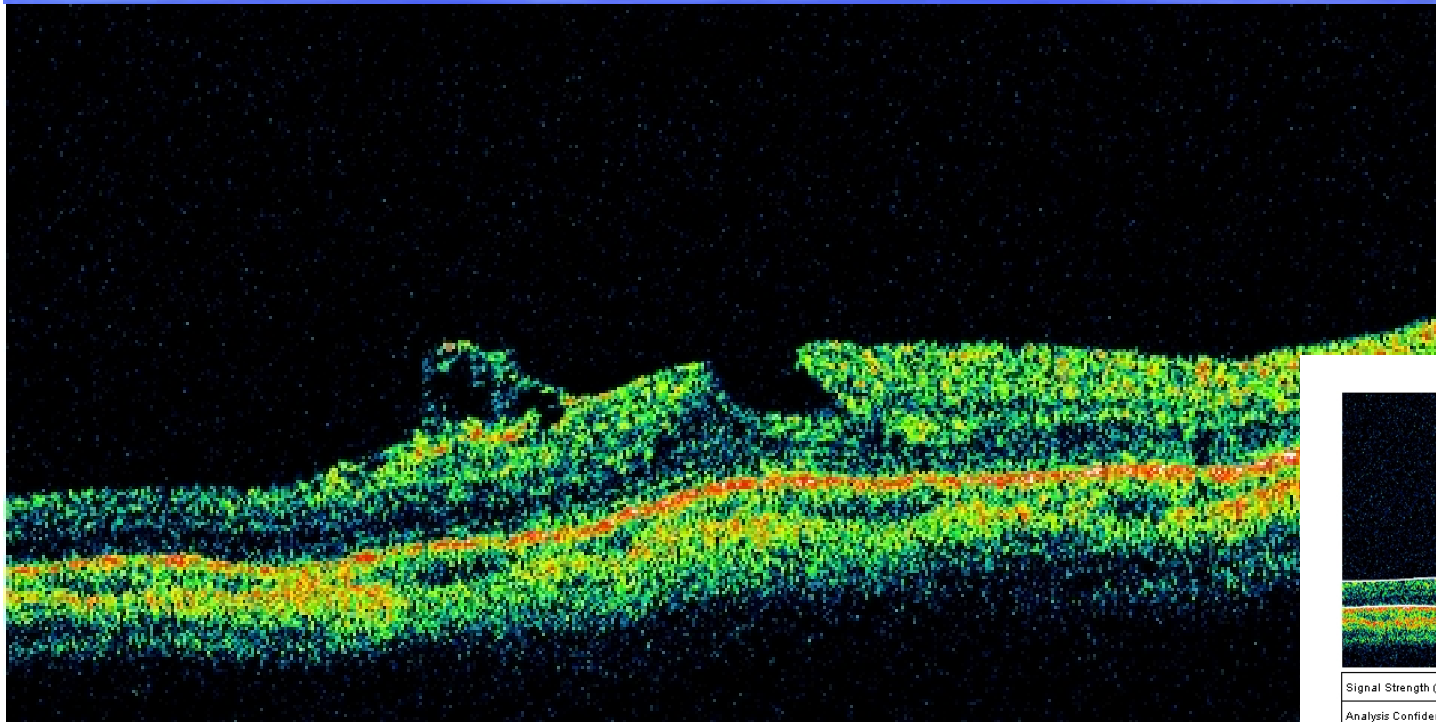
Caso Clinico

- CA, donna di 65aa
- Miopia elevata, pseudofachia bilaterale
- VOD 0.8 cc
- VOS 0.2 cc
- SP OU lacquer cracks, OS trazione interpapillomaculare

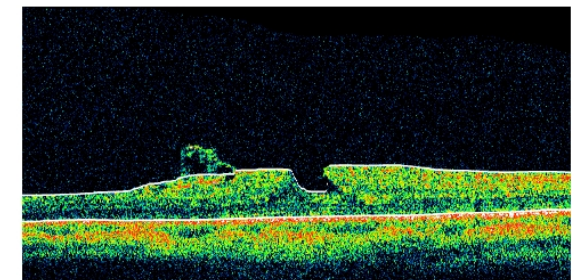


Fabrizio I

Caso Clinico, OD

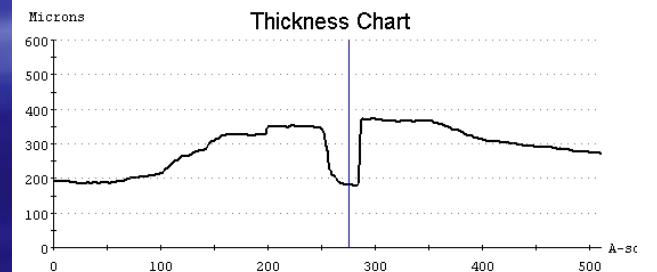
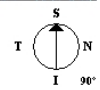


OCT Image

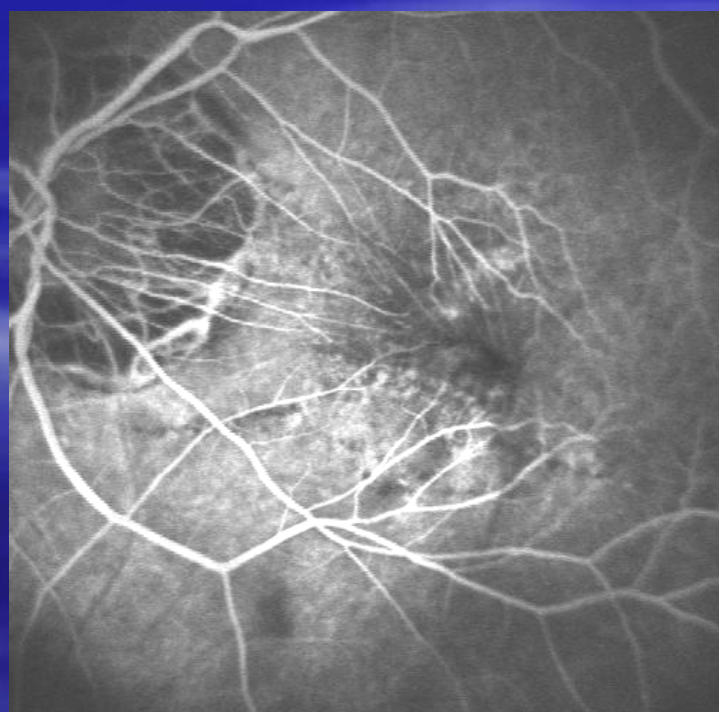
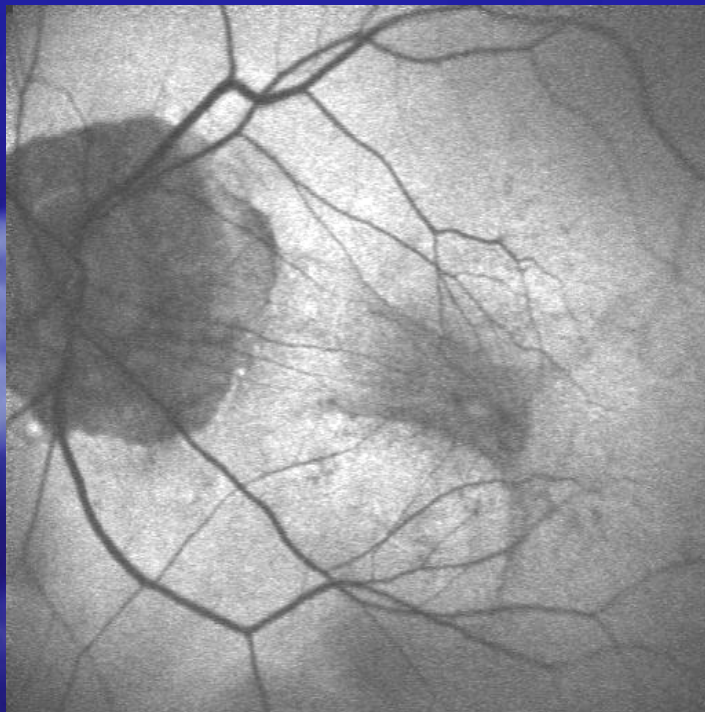
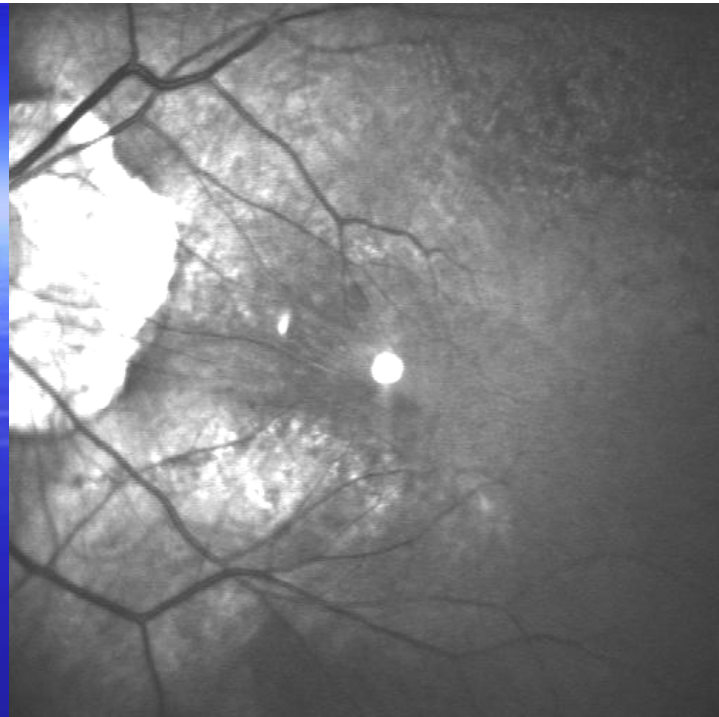
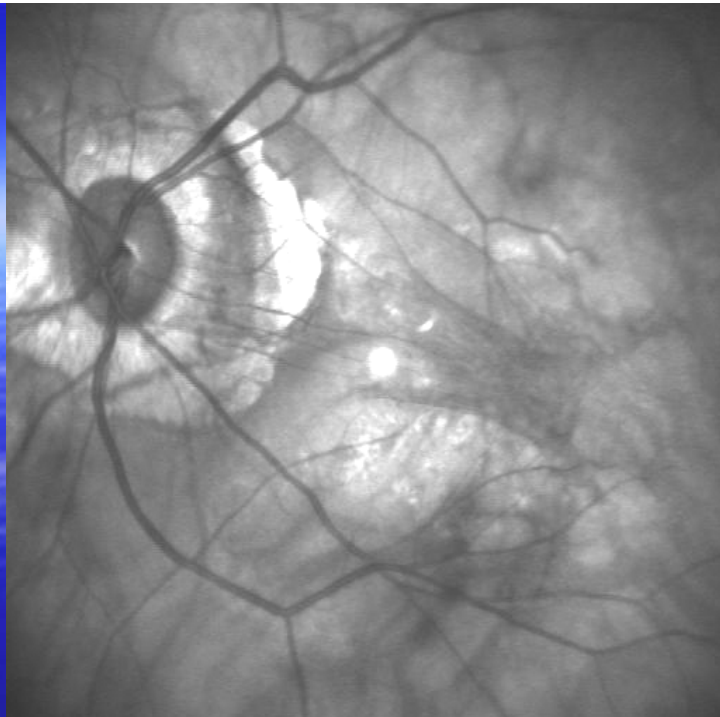


Signal Strength (Max 10) 7
Analysis Confidence Low

A-Scan value 276 Mirror Image Caliper On Layer ON

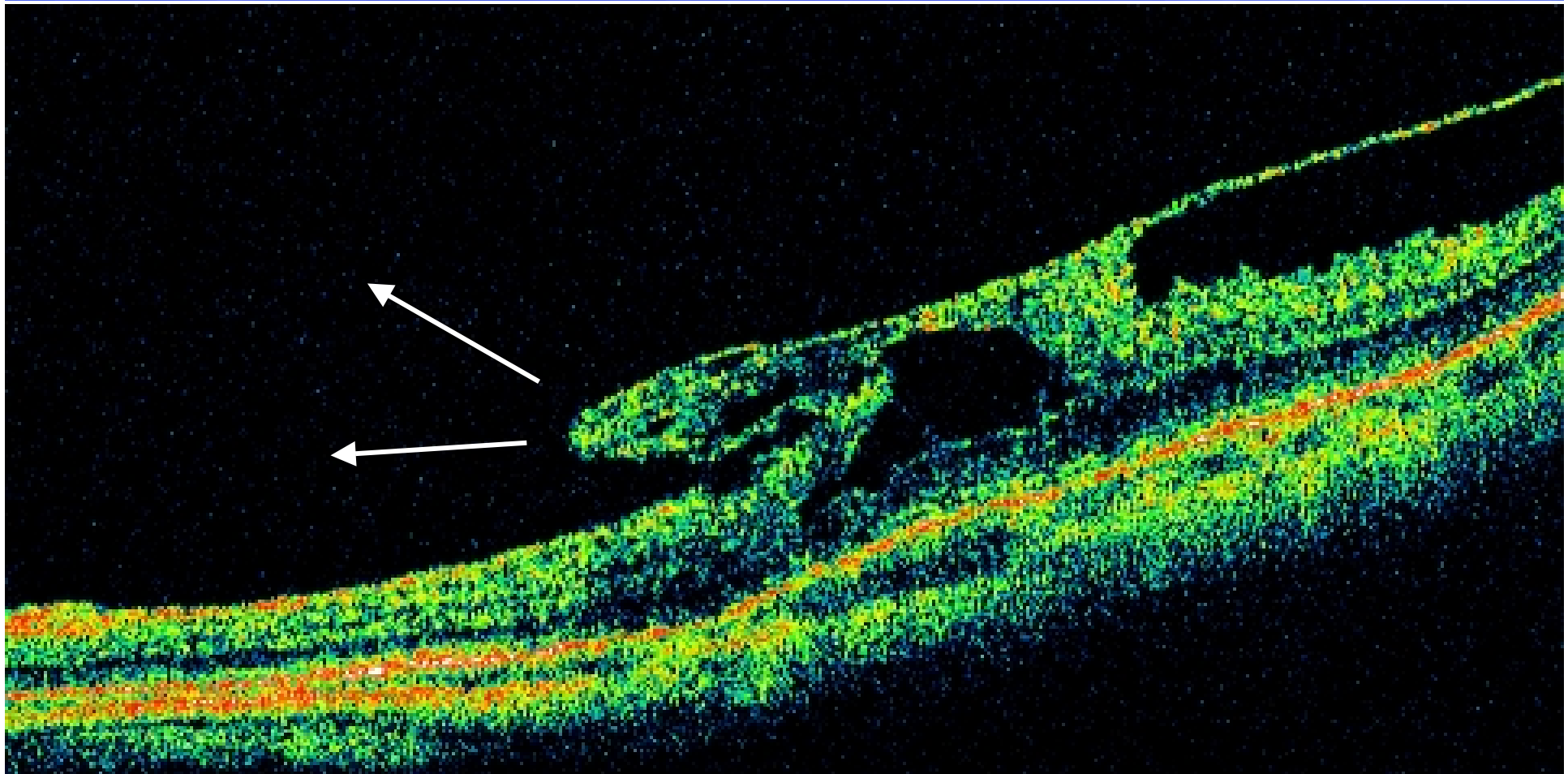


Fabrizio I. Camesasca M.D.



Fabrizio

Caso Clinico, OS

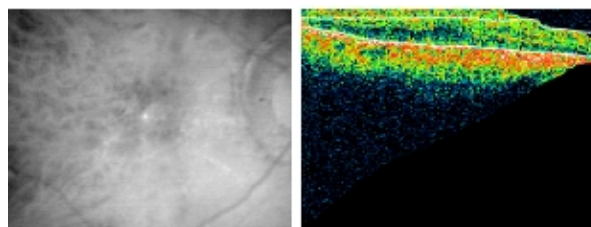


Fabrizio I. Camesasca M.D.

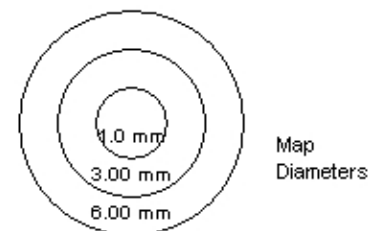
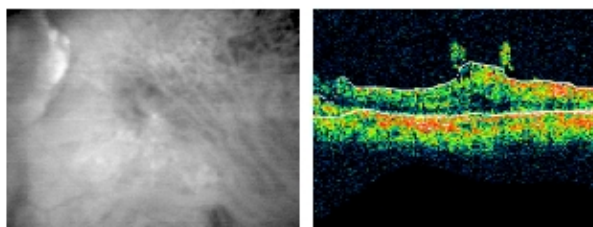
RETINAL THICKNESS/VOLUME ANALYSIS



OD



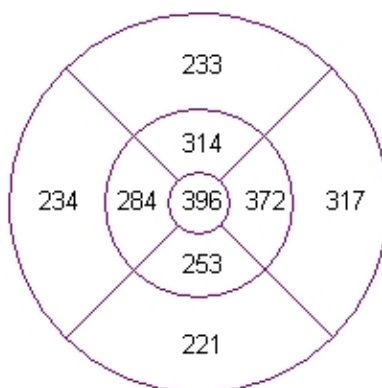
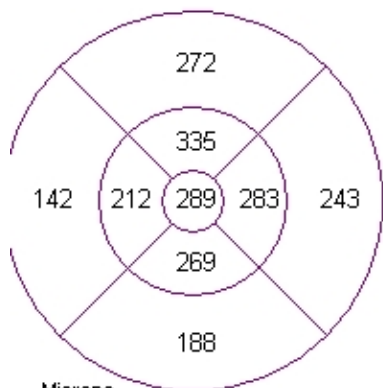
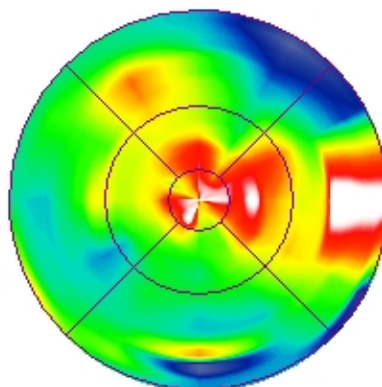
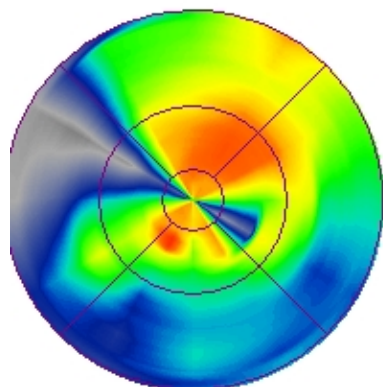
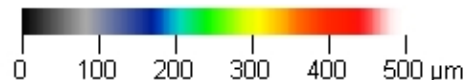
OS



| | |
|--------------------------|---|
| Signal Strength (Max 10) | 8 |
| Scan too high | |

| | |
|--------------------------|---|
| Signal Strength (Max 10) | 7 |
| Analysis Confidence Low | |

- Thickness Analysis
- Volume Analysis
- 3.45 mm
- 6 mm



| | | |
|----|----------------------|----------------------|
| OD | Foveal Thickness | 286 +/- 80 microns |
| | Total Macular Volume | 6.45 mm ³ |
| OS | Foveal Thickness | 412 +/- 74 microns |
| | Total Macular Volume | 7.58 mm ³ |

| Patient/Scan Information | |
|--|----------------------------|
| casioli agnese | |
| DOB: 8/12/1944, ID: NA, Gender unknown | |
| Scan Type | Fast Macular Thickness Map |
| Scan Date | 10/11/2007 |
| Scan Length | 6.0 mm |

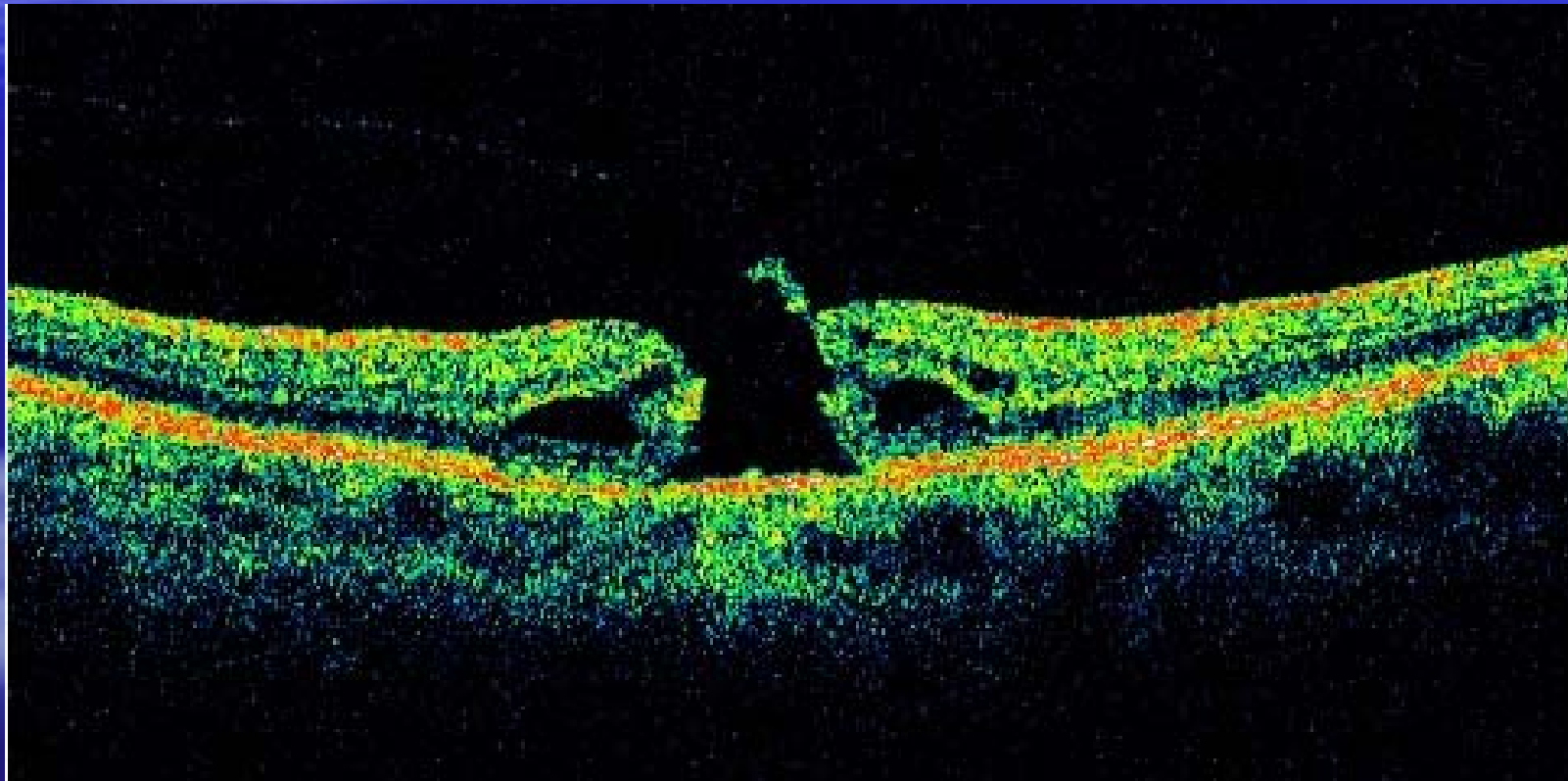
Caso Clinico

- Giustificato sospetto clinico, OS
- Sorpresa... OD
- Cambiamento del possibile programma terapeutico, da osservazione a chirurgia vitreoretinica
- Efficace Collaborazione tra Ospedali !!

Foro Maculare

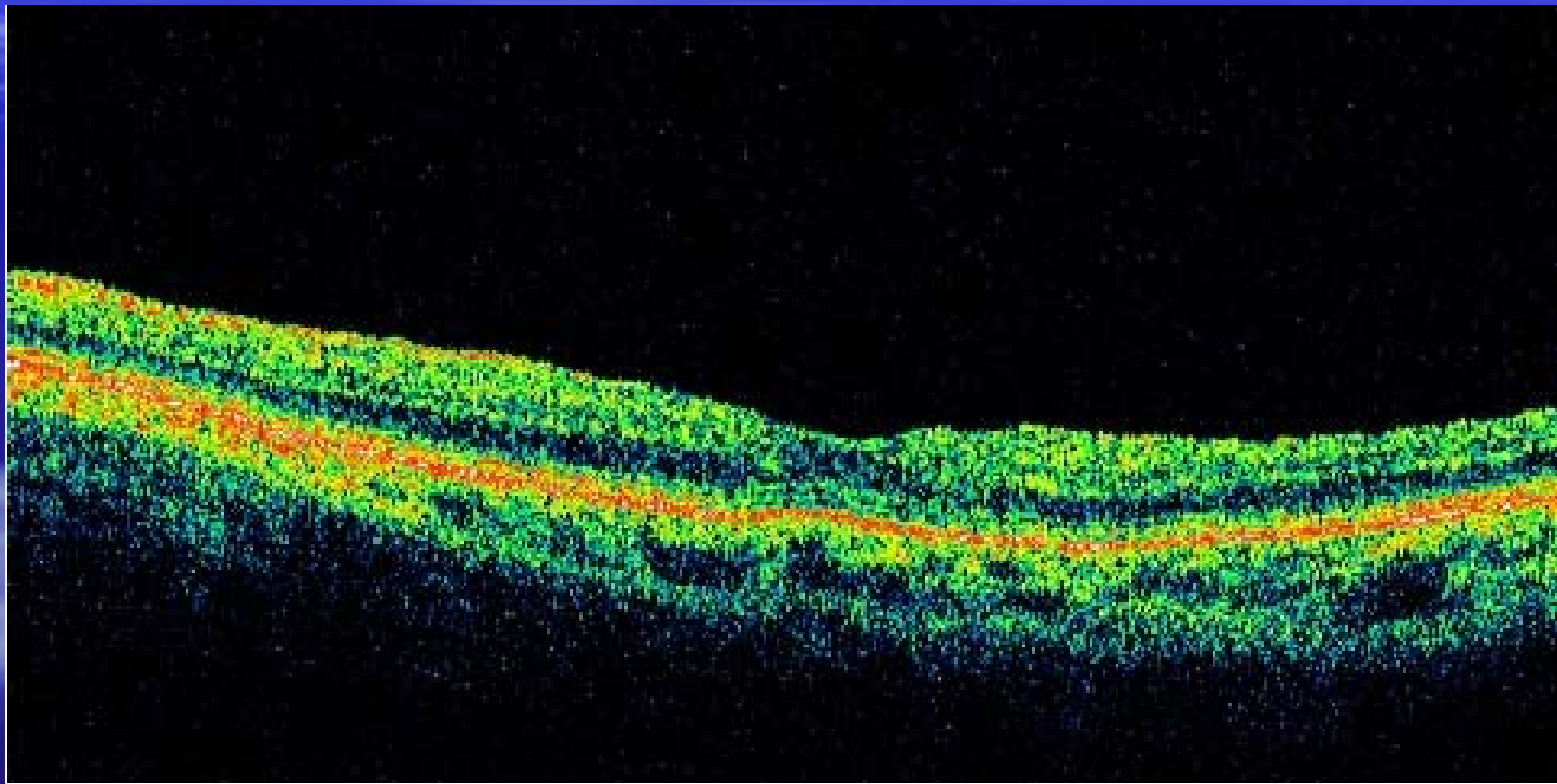
BS, donna di 62 aa

VOS 0.45 -10.50 -1.00 (135), con scotoma centrale



Foro Maculare

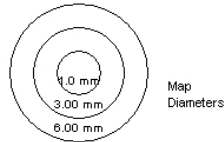
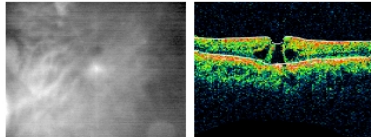
Operata per cataratta, TPPV + peeling + PDMS
6 mesi postop: VOS 0.8 -2.25 -1.25 (15)



Foro Maculare

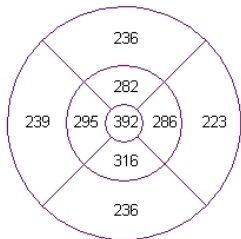
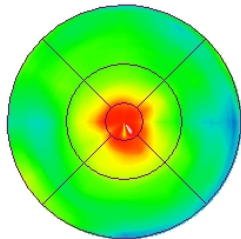
RETINAL THICKNESS/VOLUME ANALYSIS

OS



| | |
|--------------------------|---|
| Signal Strength (Max 10) | 7 |
|--------------------------|---|

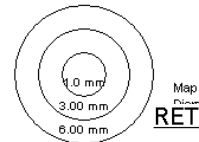
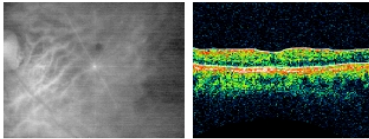
- Thickness Analysis
- Volume Analysis
- 3.45 mm
- 6 mm



Microns

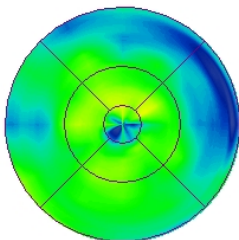
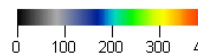
RETINAL THICKNESS/VOLUME ANALYSIS

OS



| | |
|--------------------------|---|
| Signal Strength (Max 10) | 8 |
|--------------------------|---|

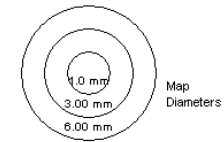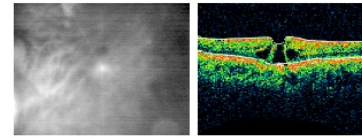
- Thickness Analy
- Volume Analysis



Microns

RETINAL THICKNESS/VOLUME CHANGE ANALYSIS

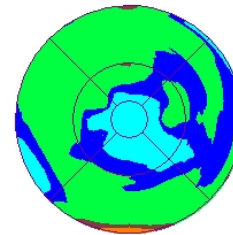
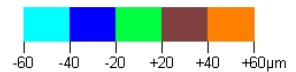
OS



| | |
|--------------------------|---|
| Signal Strength (Max 10) | 7 |
|--------------------------|---|

- Thickness Analysis
- Volume Analysis

- 3.45 mm
- 6 mm



Microns

| | |
|----|-----------|
| OD | Foveal TH |
| | Total Mac |
| OS | Foveal TH |
| | Total Mac |

| | |
|---------------------|----|
| Pz | |
| bietti silvana | |
| DOB: 12/23/1945, IT | |
| Scan Type | Fi |
| Scan Date | 2. |
| Scan Length | 6 |

| | |
|----|---------------------|
| OD | Foveal Thickness |
| | Total Macular Volum |
| OS | Foveal Thickness |
| | Total Macular Volum |

| | |
|---------------------------------|-----------------|
| Patient/Scan | |
| bietti silvana | |
| DOB: 12/23/1945, ID: NA, Gender | |
| Scan Type | Fast Macular TI |
| Scan Date | 5/30/2007 |
| Scan Length | 6.0 mm |

| | |
|---|----------------------------|
| Patient/Scan Information | |
| bietti silvana | |
| DOB: 12/23/1945, ID: NA, Gender unknown | |
| Scan Type | Fast Macular Thickness Map |
| Scan Date | 9/10/2007 - 2/7/2007 |
| Scan Length | 6.0 mm |

**Arrivederci
September 2008**

Refractive.online

